

# Ultrasonography Guided Percutaneous Ethanol Injection Therapy for Benign Thyroid Nodules: Preliminary Experience

P. K. Bhattacharjee<sup>1</sup>, R. Hoque<sup>1</sup>, T. U. Ahmed<sup>1</sup>, S. Hossain<sup>1</sup>, N. A. Alim<sup>1</sup> and R. Chakraborty<sup>2</sup>

<sup>1</sup>Institute of Nuclear Medicine and Allied sciences (INMAS), Chittagong, Bangladesh

<sup>2</sup>Chattagram Maa-O-Shishu Hospital Medical College, Chittagong, Bangladesh

## Abstract

Thyroid nodule is one of the most frequently encountered thyroid diseases. High resolution ultrasonography (US) is sensitive and capable of detecting detailed anatomy of thyroid including nodules. Tc-99m thyroid scan is a well established and inexpensive imaging modality for many thyroid disorders. The aim of this study was to detect the effectiveness of percutaneous ethanol injection therapy (PEIT) in benign cystic thyroid nodules. Twelve cystic nodules in 12 consecutive patients were enrolled in this study. Morphological evaluation and volumetric assessment of each nodule was calculated using linear transducer (7.5-10 MHz). Thyroid scan, FNA and thyroid hormone status was evaluated. After aspiration of cyst fluid, 99% ethanol was injected in each nodule under US guidance. The effectiveness of sclerotherapy was assessed by comparing the baseline volume and the volume at final follow up 1-6 years following ethanol injection. The entire group had a highly significant reduction in the initial cyst volume compared with the final volume at the late follow-up after completion of PEIT ( $P < 0.001$ ). We found negative correlation between total volume and number of ethanol injection with the volume reduction rate ( $R^2$  linear = 0.224 & 0.226) respectively. Baseline Tc-99m thyroid scan showed cold area in all seven cystic nodules & three complex nodules (total 83.33%) and rest two complex nodules (16.67%) were partially cold. However, in the final follow up Tc-99m scan, no focal sign or any cold area was detected in five cases (41.67%). Rest seven cases (58.33%) showed reduction of nodule size and improved functional status revealed as radiotracer distribution at the previous cold nodular areas. In conclusion, US-guided percutaneous ethanol injection is an effective, safe, well-tolerated and inexpensive outpatient procedure for the treatment of benign cystic thyroid nodules.

**Keywords:** Benign thyroid nodule, ethanol injection, thyroid scan, high resolution ultrasonography

## 1. Introduction

Thyroid nodule which is one of the most frequently encountered thyroid diseases is characterized by growth of abnormal tissues into the thyroid gland. Its incidence varies among population of different geographic regions [1]. Now a day, more frequent use of imaging modalities, thyroid nodules have been detected in individuals with complaints, and many asymptomatic patients as well. The introduction of highly sensitive imaging techniques has made it possible to detect many nonpalpable nodules, or “incidentalomas,” in the thyroid. High resolution ultrasonography is sensitive and capable of detecting many small, non-palpable thyroid nodules. Most of these lesions are benign [2]. Discovery of these lesions raises concerns about their malignancy, but the optimal strategy for managing these lesions has not been clearly established. The contents of a thyroid nodule can be solid or cystic in various proportions. According to various studies, 15–30% of thyroid nodules are cystic or predominantly cystic [1-3]. Goiter and the associated thyroid nodules result in anxiety, cosmetic disfigurement, and rarely compressive symptoms necessitating surgical removal, a procedure inherently associated with risks and complications.

Conventional treatment of thyroid nodules is surgical excision. In simple benign cystic thyroid nodules, cosmetic reasons, local compression, and pain are the most frequently seen treatment indications. Conventional surgery for smaller lesions is not preferred by surgeons. Besides, complications mostly related to open surgery as bleeding, wound site infection, recurrent laryngeal nerve damage, and

scar formation have prompted surgeons to opt for minimally invasive surgical methods. To that end, many procedures like cyst aspiration, injection of sclerotic agents into the cyst, radiofrequency ablation of the cyst or laser photo fulguration have been employed [4-5]. Increased recurrence rates after simple cyst aspiration, higher cost of laser or radiofrequency ablative procedures have been the most important disadvantages of these methods. According to the American Thyroid Association and the European Thyroid Association, a conservative (or nonsurgical) approach should be used for benign cystic thyroid nodules [3]. Application in a short time as a day care surgery on ambulatory patients with its minimal, and acceptable side effects, and lower cost can be regarded as advantages of ethanol injection therapy, preferable with US guidance.

In this study, in the light of literature findings, we aimed to present results of our patients with benign cystic thyroid nodules treated using US guided percutaneous ethanol injection therapy (PEIT).

## 2. Materials and Methods

Twelve thyroid nodules in 12 consecutive patients (seven females, five males; mean age  $41.42 \pm 9.59$  years; age range 25-55 years; Urban five Vs Rural seven) were treated at the outpatient clinic of our institute (INMAS, Chittagong) between March 2010 and December 2015. A case was considered for PEIT if it met all the following selection criteria: 1) age >18 years; 2) normal/ mildly decreased thyroid function; 3) no major concomitant disorders; 4) no history of neck or thyroid irradiation; 5) cystic or predominantly cystic (>70 % cystic component) thyroid nodule; 6) compressive symptoms or aesthetic complaints; and 7) voluntary patient decision to undergo PEIT instead of open surgery after careful explanation of

the procedure. The study was conducted in accordance with the Declaration of Helsinki. All participants gave their written informed consent. In all cases, a medical history was taken and physical examination performed and blood samples were obtained for analytical assess. Serum total triiodothyronin (T3), thyroxin (T4) and thyroid stimulating hormone (TSH) were measured by using radioimmunoassay/immunoradiometricassay.

Among the 12 patients, four (33.33%) had multinodular goiter and rest eight (66.67%) had solitary nodular goiter. In case of MNG, we selected the most dominating nodule fulfilling the criteria of inclusion.

All study population in our study underwent Tc-99m thyroid scan twice; baseline scan was done before starting sclerotherapy and 2<sup>nd</sup> scan at the final follow up 1-6 years following ethanol injection. Scan was taken 20 min after the injection of two mCi Tc-99m in each patient. Scan report was analyzed by two experienced nuclear medicine physicians at our institution.

An US examination was performed in each patient by two experienced physician using a high resolution 7.5-10 MHz linear transducer device (SA 9900 Prime, Medison). Morphological evaluation included description of the thyroid echotexture and measurement of the diameters and ultrasound characteristics of each detected nodule. Nodules having one or more high risk features of malignancy on US (irregular margins, nodules taller than broader, loss of peripheral halo, microcalcifications, increased central vascularity) were excluded from the study [6]. Volumetric assessment of the nodules was based on the use of an ellipsoid model [7]. With this rotating ellipsoid model, the height, width and depth of each nodule were measured. The obtained result was then multiplied by the mathematical constant or correction factor 0.524 [8]. Fine needle aspiration cytology was performed and all with benign cytology were included in study.

Positions of the patient and operator were similar to those of the FNA (fine needle aspiration cytology) procedure, with the patient lying with their neck in hyperextension. After skin sterilization, and under ultrasound guidance, a 21 G needle and a 10 ml syringe were used to empty the contents of the cyst. Subsequently, 99 % ethanol was injected with a slow movement of the needle to reach the major part of the inner face of the cyst capsule. The patient was instructed to signal any feeling of pain to prevent the spread of alcohol into the neck structures. The amount of ethanol injected was approximately 1/3<sup>rd</sup> of the volume of liquid extracted with a maximum of 10 ml. The needle tip was constantly visualized during the procedure. In no case were more than five ml injected in a single sitting. The ethanol was not re-extracted and patients were discharged after a 20–30 minute post-procedure observation period. Three patients (25%) underwent ethanol injection thrice, five patients (41.67%) underwent the procedure twice and rest four (33.33%) patients received sclerotherapy once.

Patients were followed up at three weeks interval for initial three months, then once in every three months for up to one year and yearly thereafter. Ultrasound examination was performed at each appointment to evaluate the characteristics and volume of the residual lesion.

Therapeutic success was defined as disappearance of the fluid component and no recurrence of the cyst after more than 1-6 year follow-up. To see the effectiveness of sclerotherapy we compared baseline volume of purely cystic and complex cystic nodules with volume-reduction rate and volume at final follow up.

The volume-reduction rate was presented as follows: initial volume – final volume after treatment / baseline volume x 100%. We used unpaired t test and linear correlation coefficient r test for statistical analysis. *P* < 0.05 was taken to indicate a significant difference.

**Table 1.** Volumes and reductions of lesion in relation with aspiration findings

Aspirated fluid	Base line/initial Vol (ml) (Mean ±SD)	Total aspirated amount (ml) (Mean ±SD)	Final vol. (ml) (Mean ±SD)	Vol. reduction(ml) (Mean ±SD)	Volume reduction rate (%) (Mean ±SD)
Pale yellow (n-4)	21.18 ± 6.15	15.00 ±3.46	3.05 ±2.36	18.13 ±6.61	85.18 ±12.72
Dark (n-5)	23.20 ±17.64	16.50 ±10.01	9.80 ±11.54	13.40 ±7.86	63.99 ±13.62
Clear (n-3)	12.33 ±9.29	8.83 ±6.82	2.36 ±2.47	9.96 ±8.05	83.86 ±15.12
Total (n-12)	19.81 ±12.66	14.08 ±7.66	5.69 ±8.01	14.11 ±7.54	76.03 ±16.31

**Table 2.** US finding with ethanol used

USG findings	No. of ethanol inj (Mean ±SD)	Total Vol. of ethanol inj (ml) (Mean ±SD)
Cystic (n-7)	1.57 ±0.53	3.79 ±1.62
Complex (n-5)	2.40 ±0.89	5.30 ±3.27
Total (n-12)	1.92 ±0.79	4.42 ±2.43

**Table 3.** Initial and final volumes of thyroid nodules within the study subjects (with paired t-test significance)

Volume of nodule	N	Mean	± SD	Range	Significance*
Initial Volume (ml)	12	19.81	12.66	2 – 50	P = 0.000 HS
Final Volume (ml)	12	5.69	8.02	0.1 – 30	

\* Paired samples t-test. HS = Highly Significant (*P* < 0.001)

**Table 4.** Aspirated content in relation with ultrasound features

Aspirated contents	Ultrasound features				Total	
	Pure cystic		Complex cyst		n	%
	n	%	n	%		
Dark	0	0.0	5	100.0	5	41.7
Clear	3	42.9	0	0.0	3	25.0
Pale yellow	4	57.1	0	0.0	4	33.3
Total	7	100.0	5	100.0	12	100.0

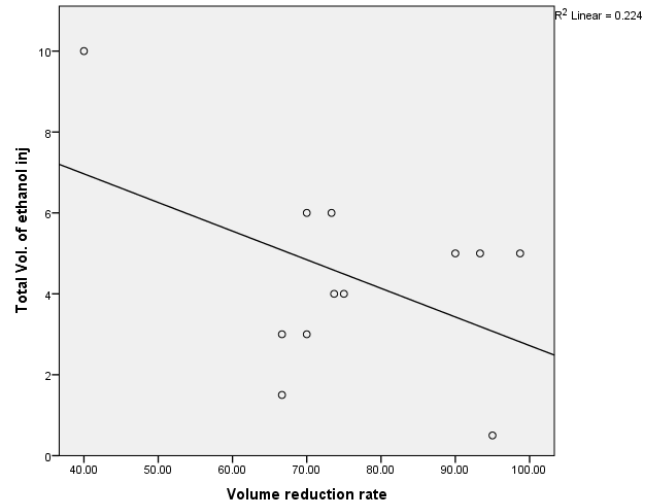
**3. Results**

In all 12 patients, US-guided PEIT was successful and the desired effect was achieved, that is, shrinkage of the cystic cavity and no recurrence during the early long-time follow-up (Table 1). The subsequent long-term follow-up, more than one year intervals, ranged from more than one year to six years in all patients, with no recurrence of sclerotized cysts in any of them. PEIT was performed once in four patients (33.33%), twice in five patients (41.67%) and three times in three patients (25%). The mean number of PEIT procedures was (1.92±0.79) with a mean ethanol volume of 4.42±2.44 ml. The total amount of instilled ethanol ranged from 0.5 ml to 10 ml, accounting for approximately 1/3<sup>rd</sup> of the initial cyst volume (Table 2). The entire group had a highly significant reduction in the initial cyst volume compared with the final volume at the late follow-up after completion of PEIT (P<0.001; Table 3).

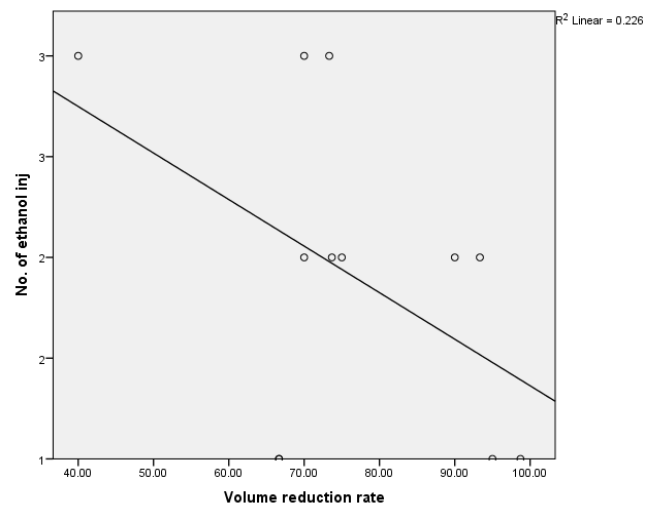
Fig. 1 and Fig. 2, showed negative correlation between total volume and number of ethanol injection with the volume reduction rate (R<sup>2</sup> linear = 0.224 & 0.226), respectively. The initial/baseline cyst volume ranged from two ml to 50 ml, with a mean volume of 19.81±12.66 ml, seven (58.33%) patients had pure cysts, with ultrasound scans showing a cystic component of more than 90%, anechoic content and smooth internal wall; the drained fluid was viscous, clear or pale yellow, five (41.67%) patients had complex cysts, with ultrasound scans showing a fluid component of 70-90% of the volume, anechoic to fine echoes in fluid with roughened wall and septa in some cysts; the aspirated fluid was viscous, dark yellow or brown with sediments (Table 4).

In our study, the volume reduction at final follow up was not the only observation, also there was some changes in morphology after PEIT; all nodules were solidified; focal macro-calcifications appeared mostly in the central part in five (41.67%) of them (Fig. 3A-3B, 4A-4B).

Among 12 patients, initial pre-procedure Tc-99m thyroid scan showed purely cold area in all seven cystic nodules & three complex nodules (total 83.33%) and rest two complex nodules (16.67%) were partially cold. However, in the final follow up Tc-99m scan, no focal sign or any cold area was detected in five cases (41.67%). Rest seven cases (58.33%) showed reduction of nodule size and improved functional status revealed as radiotracer distribution at the previous cold nodular areas (Fig. 4C-4D).

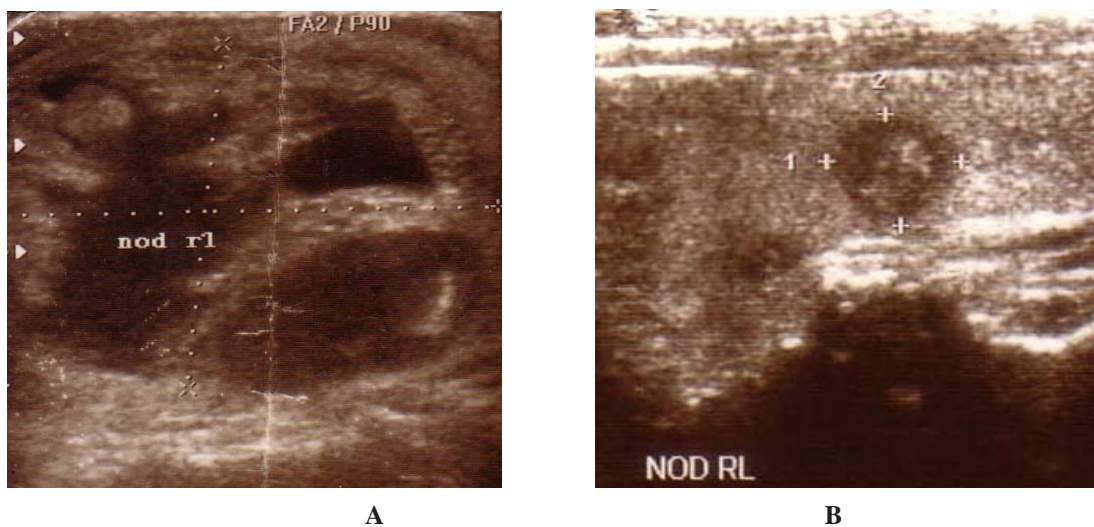


**Fig. 1** Correlation of total volume of ethanol used with volume reduction rate

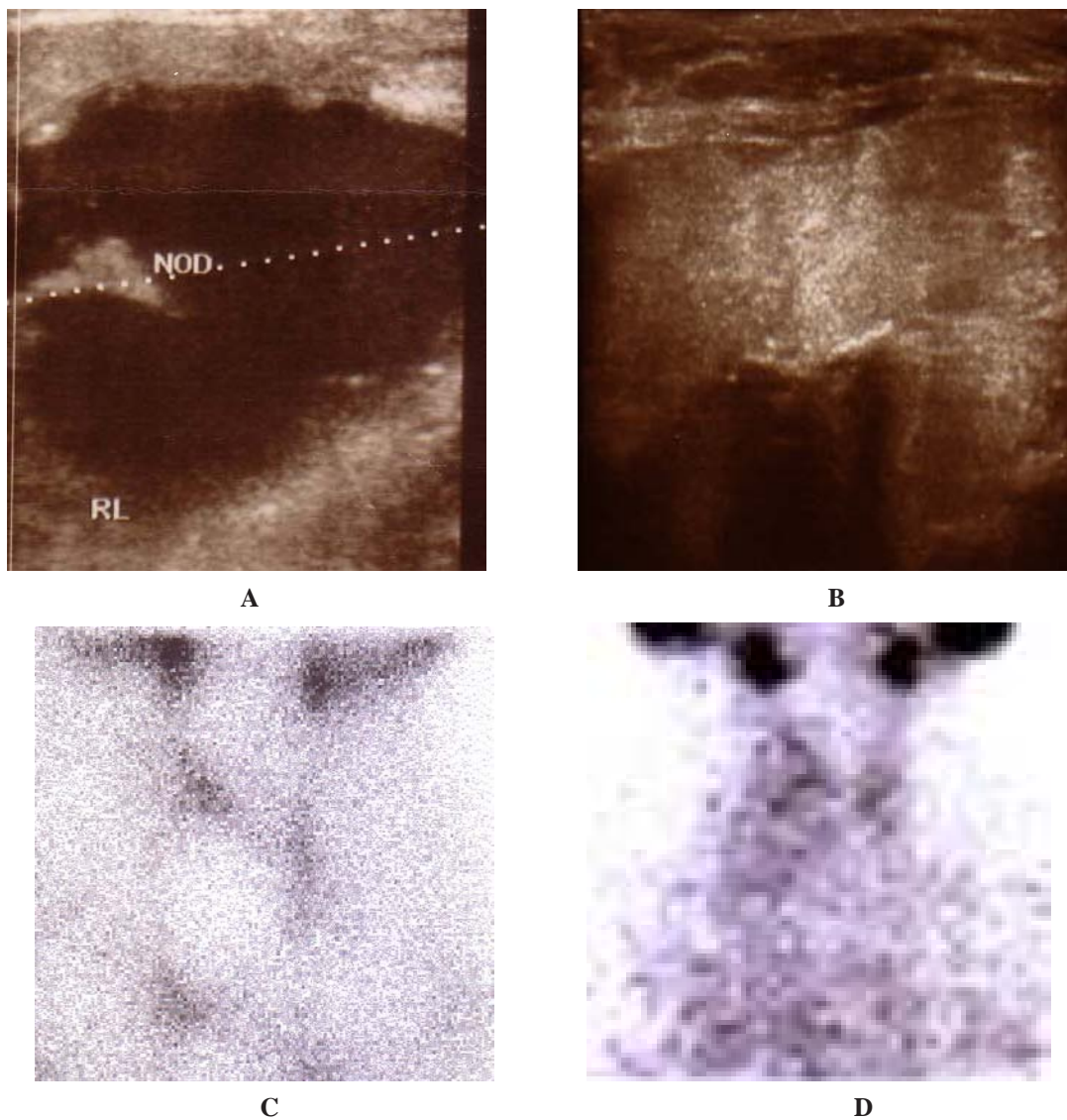


**Fig. 2** Correlation of number of ethanol injection used with volume reduction rate

Apart from temporary mild localized pain following application of ethanol, reported by about 33.33% of patients and lasting for 8 h to 24 h (often as negligible, never as strong), no serious complications were observed. Pain was relieved by NSAID. Local anesthesia was not administered.



**Fig. 3** Thyroid nodule in right lobe, A) before and B) after PEIT at final follow up after 6 years



**Fig. 4** Thyroid nodule in right lobe, before A) US, C) Tc-99m scan and after PEIT at final follow up 5 years later B) US, D) Tc-99m scan

#### 4. Discussion

The first step in the selection process of the treatment modality for thyroid cysts is to decide whether the cyst is benign or malignant. To that end, cyst contents should be aspirated, and aspirate should be examined histopathologically. This approach has both diagnostic and therapeutic implications [9]. Use of simple aspiration in the management of cystic thyroid nodules is limited by a high recurrence rate of up to 80%, which lead to the development of sclerotherapy of thyroid nodules [10].

Currently, PEIT is the first-line therapy in benign recurrent thyroid cysts. Treatment of thyroid cysts with PEIT was first proposed in 1987 by Edmonds *et al* [11] and later in 1989 by Rozman *et al.* [12]. Sclerosing properties of ethanol have been known for many years. Ethanol causes complex and irreversible tissue injury. The proposed mechanism of action is as follows: after injection of ethanol into the nodule, there is epithelial cell dehydration and protein denaturation. This is followed by coagulative necrosis, reactive fibrosis and small vessel thrombosis, which result in the obliteration of the cyst [10].

US-guided PEIT for autonomous solid thyroid nodule was first proposed by Livraghi *et al.*, [10] in 1990. After documenting their initial successes, they evaluated the long-term efficacy of this treatment modality and reported that patients who had had complete and partial cure did not show any recurrence during a follow-up period of six months to four years.

Verde *et al.*, [13] showed that nodule volume reduction was significantly greater and more significant in patients treated with ethanol injection than in patients who had treatment with just aspiration.

In a randomized study, Bennedbaek and Laszlo Hegedus [14] showed an overall success rate of 82%, with 64% patients showing significant reduction in cyst volume after the first treatment. According to their experience and other published studies on ethanol sclerotherapy, success is defined as near-disappearance or marked size reduction (>50%) of cystic lesion. In our study, 11 out of 12 patients (91.67%) showed complete disappearance or >50% reduction in cyst volume at the end of 12-72 months' follow-up. Four out of 12 patients (33.33%) in our study showed a significant reduction in cyst volume after the first treatment.

A major concern in all interventional procedures is patient comfort and the cost-effectiveness. PEIT was found to be safe, well-tolerated in our study without any major complications. This is similar to previous reports which have also suggested PEIT to be safe with the common adverse effects being local pain, dizziness, flushing, dysphonia, and very rarely recurrent laryngeal nerve damage [14]. Pain was discrete and transient in most cases. Local pain is believed to be due to leakage of ethanol into the subcutaneous tissue [15]. The cost of our procedure was very low in comparison with any surgical procedure.

Hospitalization was not required as the procedure can be carried out as an out-patient procedure with few and only

transient complications. Limitations of this study include the small number of patients.

All patients underwent Tc-99m thyroid scan in initial diagnosis before to start the treatment (aspiration and ethanol injection) and at final follow up. At Tc-99m thyroid scan, nodules were either purely cold (83.33%) or partially cold (16.67%). However, at the final follow up scan, we could not find any focal sign or cold area in five cases (41.67%) because of too small size of nodules as revealed by ultrasound (0.1-0.2 ml final volume). Rest seven cases (58.33%) showed reduction of nodule size and increased functional status revealed by radiotracer accumulation in initial cold nodular area, though the intensity of accumulation were less compared to normal thyroid tissue. This finding may explained as the reduction of the nodule was predominantly be involve the cystic part resulting presence of solid part in the final follow up which accumulates Tc-99m representing the overt functioning status of thyroid parenchyma.

Three of 12 cases (25%) with MNG had mild hypothyroidism and we included those patients in our study after being euthyroid by thyroxin replacement. We prescribed low dose of thyroxin (25-50 µg daily) in rest nine cases (75%) with euthyroid state for 3-6 months at the beginning of PEIT just to suppress S. TSH temporarily.

In our study, we found the negative correlation between number and volume of ethanol injection with volume reduction rate. In our experience, we observed that small and purely cystic nodules showed quick response even after a single PEIT, however relatively larger and more complex cysts especially that contained dark fluid showed reaccumulation needed repeated PEIT.

#### Conclusion

US-guided percutaneous ethanol injection is an effective, safe, well-tolerated and inexpensive outpatient procedure for the treatment of benign thyroid nodules, leading to reduction of nodular volume, with a low rate of early and late clinical complications; achieving relief or the disappearance of the aesthetical complaints and/or compressive symptoms. Large prospective studies need to evaluate whether response is sustained. In our opinion, future guidelines should include PEIT prior to surgical treatment and establish a uniform consensus protocol.

#### Reference

1. E. L. Mazzaferri, Management of a Solitary Thyroid Nodule, *N Engl J Med.*, **328**, 553-559 (1993).
2. G. H. Tan and H. Gharib, Thyroid Incidentalomas: Management Approaches to Nonpalpable Nodules Discovered Incidentally on Thyroid Imaging, *Ann Intern med*, **123(3)**, 226-231 (1997).
3. H. Gharib, E. Papini, R. Paschke, D. S. Duick, R. Valcavi, L. Hegedüs and et al., AACE/AME/ETA Task Force on Thyroid Nodules. American Association of Clinical Endocrinologists, Associazione Medici

- Endocrinologi and European Thyroid Association Medical Guidelines for Clinical Practice for The Diagnosis And Management of Thyroid Nodules, *Endocr Pract.*, **16**, 1-43 (2010).
4. J. H. Lee, Y. S. Kim, D. Lee, H. Choi, H. Yoo and J. H. Baik, Radiofrequency Ablation (RFA) of Benign Thyroid Nodules in Patients Within Completely Resolved Clinical Problems After Ethanol Ablation (EA), *World J Surg*, **34**, 1488-1493 (2010).
  5. Y. S. Cho, H. K. Lee, J. M. Ahn and et al., Sonographically Guided Ethanol Sclerotherapy for Benign Thyroid Cysts: Result in 22 Patients, *AJR Am J Roentgenol*, **174**, 213-216 (2000).
  6. E. K. Kim, C. S. Park, W. Y. Chung, K. K. Oh, D. I. Kim, J. T. Lee and et al., New Sonographic Criteria for Recommending Fine-Needle Aspiration Biopsy of Nonpalpable Solid Nodules of The Thyroid, *AJR Am. J. Roentgenol.*, **178**, 687-691 (2002).
  7. J. Brunn, U. Block, G. Ruf, I. Bos, W. P. Kunze and P. C. Scriba, Volumetric Analysis of Thyroid Lobes by Realtime Ultrasound [in German], *Dtsch Med Wochenschr*. **106**, 133801340 (1981).
  8. W. Shabana, E. Peeters and M. Maeseneer. Measuring Thyroid Gland Volume: Should We Change The Correction Factor? *AJR Am J Roentgenol*, **186**, 234-236 (2006).
  9. B. Cetin1, K. Duman, U. Karapinar, O. Saglam and E. Dursun, Percutaneous Ethanol Injection into Thyroid Cysts., *J Med Updates*, **3(3)**, 142-145 (2013).
  10. T. Livraghi, A. Paracchi, C. Ferrari, E. Reschini, R. M. Nacchi and A. Bonifaino, The Treatment of Autonomous Thyroid Nodules With Percutaneous Ethanol Injection: 4 Year Experience, *Radiology*, **190**, 529-533 (1994).
  11. C. J. Edmonds and Z. M. Telle, Thyroid Cysts and Their Managements, *Br Med J.*, **295**, 529-533 (1987).
  12. B. Rozman, Z. Bence-Zigman, H. Tomic-Brzac, F. Skreb, Z. Pavlinovic and I. Simonovic, Sclerosation of Thyroid Cysts by Ethanol, *Periodicum Biologorum*, **91**, 1116-1118 (1989).
  13. G. Verde, E. Papini, C. M. Pacella C. Gallotti, S. Delpiano, S. Strada and et al., Ultrasound Guided Percutaneous Ethanol Injection in The Treatment of Cystic Thyroid Nodules, *Clin Endocrinol*, **41**, 719-724 (1994).
  14. F. N. Bennedback and L. Hegedus, Treatment of Recurrent Thyroid Cysts With Ethanol: A Randomized Double-Blind Controlled Trial, *J Clin Endocrinol Metab.*, **88**, 5773-5777 (2003).
  15. V. S. Kanotra, M. Lateef and O. Kirmani, Non-surgical Management of Benign Thyroid Cysts: Use of Ultrasound-Guided Ethanol Ablation, *Postgrad Med J.*, **84**, 639-643 (2008).